

# The effect of Arabic gum on gentamycin nephrotoxicity in mice: a pathological study

Liqaa Khalel Alhyali<sup>1\*</sup>, Firas Mohammed Abed<sup>2</sup>, and Entisar Rahem AL-Kenanny<sup>3</sup>

<sup>1</sup>Department of Pathology, College of Medicine, University of Mosul, Mosul, Iraq; <sup>2</sup>Department of Pathology and Poultry Diseases, College of Veterinary Medicine, University of Mosul, Mosul, Iraq; <sup>3</sup>Dentistry College, Al-Iraqia University, Baghdad; Iraq

## ABSTRACT

**Aim** To investigate the effect of Arabic gum on gentamycin nephrotoxicity in mice kidney.

**Methods** Forty (40) mice were divided into five groups, eight mice in each. Group one (G1) stands for the negative control group. The second one (G2) was injected with gentamycin only, while the third one (G3) was given an Arabic gum orally 10g/kg. The 4th group (G4) was injected with gentamycin for 8 days, and then followed by Arabic gum orally for 8 days. The fifth group (G5) was injected with gentamycin plus oral administration of Arabic gum at the same time. A scoring system (+1-+4) was used to grade the histological features in the kidneys.

**Results** The results revealed a significant increase in body weight in G3 group only; this group presented a significant decrease in the level of both urea and creatinine. Group G2 showed a marked elevation in both serum urea and creatinine. Acute tubular necrosis (+4), in both G2 and G5. In G3, kidney sections presented mild cell swelling of the tubular epithelium in addition to the normal architectures (score +1), while G4 sections revealed tubular hyalin cast, expansion of glomerular tufts.

**Conclusion** The research indicates that gentamycin leads to kidney damage in mice. Arabic gum could be a treatment option although additional studies are required to determine the best dosing and timing, for optimal effectiveness.

**Keywords:** creatinine, gentamycin, kidney, nephritis, urea

## INTRODUCTION

Arabic gum (AG) is a dried, sticky effusion formed of the polysaccharide Arabic gum acid's calcium, magnesium, and potassium salts (1). Gum Arabic (GA) is an effusion from an edible tree that is used extensively in industry as a stabilizer, thickener, and emulsifier, most of it is in food industry (2). Several studies have revealed that Arabic gum is a natural antioxidant, which effectively guards and treats various forms of intoxication. In addition to its powerful prophylactic role in cases of chemical toxicity from trichloroacetic acid, paraquat, and mercuric chloride (3,4), the latest study revealed that Arabic gum could prevent or treat the toxic appearances of some common drugs, including gentamicin, indomethacin, aspirin, and acetaminophen, as well as some chemotherapeutic drugs (5).

Kidney is an important organ with vital energy dependent transport process. It is widely exposed to nephrotoxicity or chronic renal failure (6). Gentamycin is a widely used aminoglycoside antibiotic for the treatment of bacterial infections. Therapeutic doses of gentamycin can produce nephrotoxicity in humans and animals (7). One of the most frequent causes of

acute renal failure is the use of this antibiotic (8). The harmful consequences of aminoglycosides, most notably ototoxicity and nephrotoxicity, have become increasingly obvious as their usage increased (9). Nephrotoxicity induced by gentamycin manifests clinically as nonoliguric renal failure due to the accumulation and localization with Golgi complex of epithelial cells (10,11). Several materials have been used for blocking the action of nephrotoxicity, for example Arabic gum, which is a biologically existing mixture be composed of Ca<sup>+</sup>, magnesium and potassium salts of the polysaccharide of gum Arabic acid (12). It is well known that consuming a significant amount of fibre rich foods has a variety of beneficial health effects, including lower mortality in people who consume a lot of whole grains (2). Gum Arabic is also applied topically to soothe irritated areas and orally to treat intestinal mucosal irritation (13). Additionally, it has demonstrated to diminish urinary nitrogen elimination by rising urea and preventing gentamycin induced nephrotoxicity (14,15). Moreover, it enhances zinc absorption and stimulation of sodium and water absorption in diarrhea (16). Gum Arabic is well tolerated and has considerable positive benefits when given to people with chronic kidney disease (CKD) who are experiencing a progressive decline in their kidney function (2).

This study attempts to check whether a treatment with Arabic gum powder would have an effect on the pathological changes from gentamycin nephrotoxicity in mice.

\*Corresponding author: Liqaa Khalel Alhyali  
Phone: +964 7736976251  
E-mail: [iqqakhalelhyali@uomosul.edu.iq](mailto:iqqakhalelhyali@uomosul.edu.iq)  
ORCID: <https://orcid.org/0000-0003-2669-0989>

## MATERIALS AND METHODS

### Materials and study design

Forty male mice weighting 22-25 gram were used for the experiment. The mice were housed under normal stable temperature and 12hrs day – night cycle, fed ad libitum. The mice were housed in the Laboratory for Animals at the Department of Pathology and Poultry Diseases of Veterinary Medicine in Mosul University. This study was conducted between April and November 2022.

Ethical approvals for handling laboratory animals in a humane manner were obtained from the College of Veterinary Medicine, University of Mosul.

### Methods

Animals were divided in five groups with eight mice in each. Group one (G1), which was considered as a control group, received only normal diet and water throughout the period of the study. The second group (G2) received daily intraperitoneal injection of gentamycin 40 mg/kg of body weight (BW) for eight days (Gentamycin Megental, Sandoz, Parma, Italy). The animals of the third group (G3) received Arabic gum orally 10g/kg of BW even for eight days as the 2nd group (Dar Savvna Ltd., Khartoum, Sudan). Group four (G4) received 40 mg/kg BW of gentamycin intraperitoneally for eight days then Arabic gum orally in the dose 40 g/kg BW. Group five (G5) received gentamycin in the same dose and period as the group G4.

In the end of the experiment, all 40 male mice were starved for 12 hrs. For the examination of blood samples to detect both urea and creatinine using commercial kits (Biolabo, Maizy, France), blood samples were collected from orbital sinus orbital region under general anesthesia.

**Histopathological examinations.** Hematoxylin eosin (H&E) staining and light microscopy analysis of the kidneys from all groups were performed after they had been fixed in 10% neutral buffer formalin and processed to paraffin wax (Formalin Fixed Paraffin Embedded Tissue - FFPE) (17). They were evaluated and assigned according to scores: 0=normal, 1=centric tubular epithelial degradation and hyaline cast, 2=tubular epithelial necrosis and apoptosis, 3=more than half continual tubular epithelial desquamations with necrosis and apoptosis, and 4=complete tubular necrosis.

### Statistical analysis

The data were analysed using one way analysis of variance (ANOVA). If the ANOVA test results showed a difference ( $p < 0.05$ ) it suggested that at least one group was significantly

different from the rest leading to additional analysis to pinpoint specific variations among groups.

## RESULTS

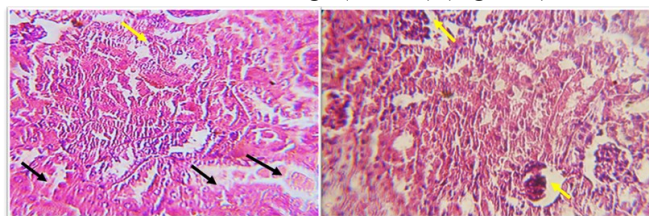
The impact of gentamycin and Arabic gum on body weight and renal function parameters (urea and creatinine) showed a significant decrease in body weight and a significant increase in urea and creatinine levels in the G2 group compared to the control group indicating nephrotoxic effect of gentamycin on renal function and body weight.

A significant increase was found in body weight and a decrease in urea and creatinine levels in the G3 group compared to the control group, suggesting that Arabic gum may have a beneficial effect on improving renal function.

An increase in body weight compared to the gentamycin group alone (G2), with a substantial increase in urea and creatinine levels was noticed in the G4 group (gentamycin then oral administration of Arabic gum); this indicates that Arabic gum may partially mitigate the toxic effects of gentamycin, but it does not completely eliminate them.

The G5 group (gentamycin plus oral administration of Arabic gum) also showed an improvement in body weight and a decrease in urea and creatinine levels compared to the gentamycin group alone (G2) suggesting that administering Arabic gum after gentamycin may help reduce the damage caused by gentamycin administration of Arabic gum and decreased the elevation of urea and creatinine (Table 1).

Mice treated with gentamycin (G2) revealed acute tubular necrosis (+4), sever acute tubular necrosis and cell swelling in some tubules with haemorrhage (Score 4) (Figure 1).



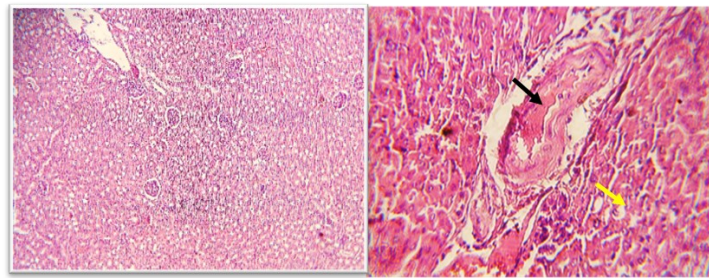
**Figure 1.** Histological sections of mice kidney treated with gentamycin show acute tubular necrosis (black arrows) and cell swelling in some tubular epithelium (yellow arrow) (left); severe acute tubular coagulative necrosis (black arrows) and expansion of glomeruli tuft (yellow arrow) (right) (100x; H&E stain)

Histological section of mice kidney treated with Arabic gum (G3) showed normal architecture of the kidney tissue, congestion of blood vessels and mild epithelial cell swelling (Score 1) (Figure 2).

**Table 1.** Impact of Gentamycin + Arabic gum on body weight and renal function parameters

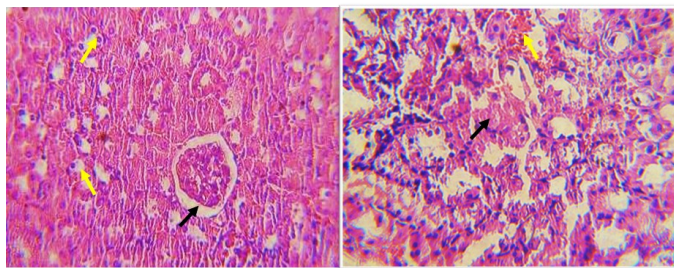
Parameter	Mean± Standard Error				
	G1 (control)	G2 (gentamycin)	G3 (Arabic gum)	G4 (Gentamycin then Arabic gum)	G5 (Gentamycin + Arabic gum)
Body weight (gm) (gram)	18.14±2.1	15.36±1.3*	21.5±1.5*†	22.3±2.1*†‡	23.11±2.2*†‡
Urea (mg/dL)	47±2.1	61±0.02*	36±1.8*†	40±2.3*†‡§	98.2±11.9*†‡
Creatinine (mg/dL)	0.78±0.04	0.90±1.02*	0.75±0.01†	0.80±0.02§	1.95±0.46*†‡ II

\*difference from control; †difference from G2, ‡difference from G3, §difference from G4, II difference from G5



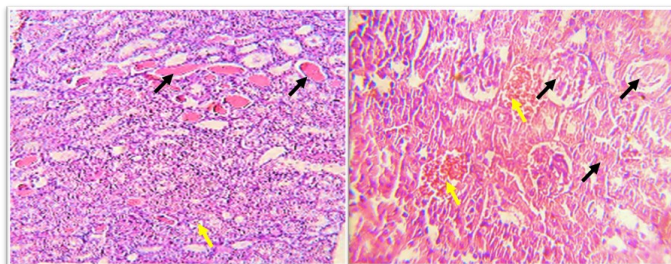
**Figure 2.** Histological section of mice kidney treated with Arabic gum shows normal architecture of the kidney tissue (left) (40x); congestion of blood vessels (black arrow) and mild epithelial cell swelling (yellow arrow) (right) (100x; H&E stain)

Histological section of mice kidney treated with gentamycin then with Arabic gum (G4) for 8 days showed tubular hyalin cast (Blue arrows), expansion of glomerular tufts (Score 2) (Figure 3).



**Figure 3.** Histological section of mice kidney treated with gentamycin then Arabic gum for 8 days: shows mild expansion of glomerular tufts (black arrow), mild vacuolar degeneration or cell swelling (yellow arrows) (left); mild tubular necrosis (black arrow), and haemorrhage (yellow arrow) (right) (100x; H&E stain)

Histological section of mice kidney treated with Gentamycin plus Arabic gum for 8 days (G5) showed severe tubular necrosis, congestion of blood vessels and dilation of urinary space as well as severe congestion associated with thickening of blood vessels and tubular necrosis (Score 3) (Figure 4).



**Figure 4.** Histological section of mice kidney treated with Gentamycin plus Arabic gum for 8 days shows presence of hyaline casts in the tubular lumen (black arrows), and glomeruli atrophy (yellow arrows) (left) (40X); severe coagulative necrosis (black arrows) and haemorrhage (yellow arrows) (right) (100X; H&E stain)

## DISCUSSION

Gentamycin nephrotoxicity handles 10-20% of all cases of acute renal failure according to experimental studies and is an oldest medication for treating severe illnesses (18). It is a major complication of the gentamycin therapy. Therefore, the conversion of nephrotoxicity would enhance its clinical value. Several material functions as antioxidant and anti-toxic have been used to meliorate gentamycin nephrotoxicity. The present study focused on the effect of Arabic gum on the renal damage induced by gentamycin.

The research findings revealed that treating mice with gentamycin at a dosage of 40mg/kg body weight for 8 days led to kidney damage. The results indicated nephrotoxicity caused by gentamycin showing harm elevated urea and creatinine levels and decreased body weight. Conversely, Arabic gum seemed to offer protection against this toxicity with improvements in body weight, renal function markers and tissue structure in groups G4 (gentamycin then oral administration of Arabic gum) and G5 (gentamycin plus oral administration of Arabic gum).

In the G5 group receiving both gentamycin and Arabic gum concurrently there was an improvement compared to the gentamycin group. However, some residual damage persisted as seen in the remaining damage and renal function markers. This suggests that, while Arabic gum can alleviate some of gentamycin's effects, its effectiveness may be limited when used together.

In group G4 where Arabic gum was administered after gentamycin exposure the improvements in kidney health and renal function were more significant. This indicates that administering gum following exposure to gentamycin could be more effective, in reducing the damage.

Reduction in blood urea and creatinine in addition to meliorated body weight and histological pictures of the kidney in the group treated with Arabic gum have an agreement with those who elucidate moderate amelioration of histological and biochemical parameters after acute gentamycin nephrotoxicity. An indication for the ability of Arabic gum to affect or block the action of gentamycin may be due to the ability of Arabic gum to act as an antioxidant, since the mechanism of action of gentamycin to induce nephrotoxicity takes place by oxidative stress (released oxygen free radicals); it has been well demonstrated in many experimental animal models (19). On the other hand, Arabic gum may prevent or diminish the accumulation of amino glycoside in proximal convoluted tubules epithelial cell, lead to membrane structural disturbances and cell death by reactive oxygen species involvement (20). An injury of tubular epithelium produced by gentamycin takes place via several mechanisms including peroxidation of membrane lipid, protein denaturation and DNA damage (21). In the G4 group administration of Arabic gum, mild melioration occurred in histological pictures; it may be due to the fact that the period of the experiment (eight days) was not enough for complete meliorations, so it needed prolonged period to give reliable results.

Those mild meliorations of Arabic gum occur due to the ability of scavenging oxygen free radicals, and in addition to Arabic gum have the ability to induce an elevation of nitrogen excretion in faeces providing an additional approach to lowering severe urea nitrogen (19). Some reports elucidate that Arabic gum works as a nephroprotective agent and would be ab-



sorbed before excreting any effect on renal function through enterosorbents' activity (22). Hyaline cast is the main change that occurs in the kidney and it may be formed due to diminished tubular reabsorption of protein, causing accumulation of these proteins within the tubular lumen. Hyaline casts are composed of solidified Tamm- Horse fall mucoprotein, which is secreted by renal tubular cells (23).

Study limitations: we used 8 mice per group which may limit the generalizability of the results; findings derived from mice may not be directly applicable to humans. Furthermore, long-term analysis and molecular mechanisms were not studied neither were the long-term effects and molecular pathways of Arabic gum evaluated.

This study demonstrates that gentamycin induces significant nephrotoxicity in mice, as observed through changes in body weight, renal function parameters, and histological damage. Conversely, Arabic gum shows a protective effect against this toxicity, with notable improvements in renal function and kidney tissue, especially when administered after gentamycin. These findings suggest that Arabic gum may be a promising adjunctive therapy for reducing the harmful effects of gentamycin treatment. However, further studies are needed to determine optimal doses and timing of Arabic gum administration to ensure maximum efficacy.

## AUTHOR CONTRIBUTIONS

Conceptualization, L.A. and F.A.; Data curation, L.A.; Formal Analysis, L.A.; Funding acquisition, L.A.; Methodology, L.A.; Resources, L.A.; Supervision, L.A. and F.A.; Validation, L.A. and F.A.; Writing – original draft preparation, L.A.; Visualization, F.A.; Writing – review & editing, F.A.; Investigation, E.A.; Project administration, E.A.; Software, E.A. All authors have read and agreed to the published version of the manuscript.

## FUNDING

No specific funding was received for this study

## TRANSPARENCY DECLARATION

Conflict of interests: None to declare.

## REFERENCES

- Prasad N, Thombare N, Sharma SC, Kumar S. Gum arabic – A versatile natural gum: A review on production, processing, properties and applications. *Ind Crops Prod* 2022;187:115304. doi: 10.1016/j.indcrop.2022.115304.
- Kadirvel V, Narayana GP. Edible gums—An extensive review on its diverse applications in various food sectors. *Food Bioeng* 2023;2;(4):384–405. doi: 10.1002/fbe2.12067.
- Nofal A, Rady M, Okdah Y, Hassaan H. Hepatoprotective Effect of Gum Arabic versus cisplatin hepatotoxicity in Adult Male Rats. *Egypt J Chem* 2023;0;(0):0–0. doi: 10.21608/ejchem.2023.175461.7203.
- Al-Hamayda A, Abu-Jdayil B, Ayyash M, Tannous J. Advances in microencapsulation techniques using Arabic gum: A comprehensive review. *Ind Crops Prod* 2023;205:117556. doi: 10.1016/j.indcrop.2023.117556.
- Ali KSE, Salih TAA, Daffalla HM. In vitro Phytochemical, Larvicidal and Antimicrobial Activities of Gum Arabic Extract. *Walailak J Sci Technol WJST* 2018;17;(3):192–9. doi: 10.48048/wjst.2020.5540.
- Braga PC, Alves MG, Rodrigues AS, Oliveira PF. Mitochondrial Pathophysiology on Chronic Kidney Disease. *Int J Mol Sci* 2022;23;(3):1776. doi: 10.3390/ijms23031776.
- Obaid SS. The medical uses of Gum Acacia-Gum Arabic (GA) in human. *Acad J Res Sci Publ* 2020;1;(10).
- Fareed SA, Almilaibary AA, Nooh HZ, Hassan SM. Ameliorating effect of gum arabic on the liver tissues of the uremic rats; A biochemical and histological study. *Tissue Cell* 2022;76:101799. doi: 10.1016/j.tice.2022.101799.
- Erseçkin V, Mert H, İrak K, Yıldırım S, Mert N. Nephroprotective effect of ferulic acid on gentamicin-induced nephrotoxicity in female rats. *Drug Chem Toxicol* 2022;45;(2):663–9. doi: 10.1080/01480545.2020.1759620.
- Fauzi A, Titisari N, Sutarsa, Mellisa V. Gentamicin Nephrotoxicity in Animal Model: Study of Kidney Histopathology and Physiological Functions. *IOP Conf Ser Earth Environ Sci* 2020;465;(1):012005. doi: 10.1088/1755-1315/465/1/012005.
- Mishra P, Mandlik D, Arulmozhi S, Mahadik K. Nephroprotective role of diosgenin in gentamicin-induced renal toxicity: biochemical, antioxidant, immunological and histopathological approach. *Future J Pharm Sci* 2021;7;(1):169. doi: 10.1186/s43094-021-00318-z.
- Alfathi M, Alabdaly Y, Al-Hayyali F. Ameliorative Effect of Spirulina against gentamicin toxicity in liver and kidney tissues of male rat. *Egypt J Histol* 2022;0;(0):0–0. doi: 10.21608/ejh.2022.155247.1750.
- Al-Ghamdi FA, Al-sulami JA, Al-Nahari H. Possible positive effect of gum Arabic against the toxicity of the drug furosemide on newborn rats: Gum Arabic. *Int J Biol Chem* 2023;16;(2):56–71. doi: 10.26577/IJBCh2023v16i2a6.
- Abdullah ATH, Ahmed MA. Ameliorative role of Arabic gum against nephrotoxicity induced by ciprofloxacin in rats. *Iraqi J Vet Sci* 2021;35;(4):789–98. doi:10.33899/ijvs.2020.127441.1503.
- Eman Aboud Hussein, Husham Qassim Mohammed. Therapeutic Effect of Gum Arabic on some Biochemical Parameters in Nephrotoxic Albino rats. *Indian J Forensic Med Toxicol* 2021;15;(2):2297–303. doi: 10.37506/ijfimt.v15i2.14713.
- Ahmed HE, Abdrahman SH, Ahmed Mohamed S, Bilal TarigAH, Elghazali FEB, Elbadwi SM. NEPHROPROTECTIVE EFFECT OF ACACIA SENEGAL (GUM ARABIC) AGAINST GENTAMICIN INDUCED NEPHROTOXICITY IN RATS. *Int J Res - GRANTHAALAYAH* 2022;10;(3):120–8. doi: 10.29121/granthaalayah.v10.i3.2022.4516.
- Noha, S, Fetaih H, Dessouki A. Effect of Gum Arabic on Chemically Induced Acute Renal Injury in Albino Rats. *Egypt Acad J Biol Sci B Zool* 2022;14;(2):411–24. doi: 10.21608/eajbsz.2022.274522.
- Al-Jubori Y, Ahmed NTB, Albusaidi R, Madden J, Das S, Sirasanagandla SR. The Efficacy of Gum Arabic in Managing Diseases: A Systematic Review of Evidence-Based Clinical Trials. *Biomolecules* 2023;13;(1):138. doi: 10.3390/biom13010138.
- Wick MR. The hematoxylin and eosin stain in anatomic pathology-An often-neglected focus of quality assurance in the laboratory. *Semin Diagn Pathol* 2019;36;(5):303–11. doi: 10.1053/j.semdp.2019.06.003.

- 20 Helmy A, El-Shazly M, Omar N, Rabeh M, Abdelmohsen UR, Tash R, et al. Increment of Lysosomal Biogenesis by Combined Extracts of Gum Arabic, Parsley, and Corn Silk: A Reparative Mechanism in Mice Renal Cells. *Evid-Based Complement Altern Med ECAM* 2020;2020:8631258. doi: 10.1155/2020/8631258.
- 21 Ranasinghe R, Mathai M, Zulli A. Cytoprotective remedies for ameliorating nephrotoxicity induced by renal oxidative stress. *Life Sci* 2023;318:121466. doi: 10.1016/j.lfs.2023.121466.
- 22 Al-Amer HA, Al-Sowayan NS, Alfheaid HA, Althwab SA, Alrobaish SA, Hamad EM, et al. Oral administration of naringenin and a mixture of coconut water and Arabic gum attenuate oxidative stress and lipid peroxidation in gentamicin-induced nephrotoxicity in rats. *Eur Rev Med Pharmacol Sci* 2023;27;(21):10427–37. doi: 10.26355/eurrev\_202311\_34317.
- 23 Gaut JP, Liapis H. Acute kidney injury pathology and pathophysiology: a retrospective review. *Clin Kidney J* 2021;14;(2):526–36. doi: 10.1093/ckj/sfaa142.

**Publisher's Note** Publisher remains neutral with regard to jurisdictional claims in published maps and institutional affiliations